Preoperative Shock Wave Therapy Reduces Ischemic Necrosis in an Epigastric Skin Flap Model

Matthias A. Reichenberger, MD,† Günter Germann, PhD, MD,*† Heinz Jürgen Roth,‡ Romed Meirer, MD,§ and Holger Engel, MD*†*

Abstract: Extracorporeal shock wave therapy (ESWT) has recently been demonstrated to improve skin flap survival. In all these studies EWST was applied immediately after the surgical intervention. Thus, the purpose of this study was to determine the preoperative effect of ESWT as a noninvasive technique to precondition flap tissue in a rat epigastric skin flap model.

EWST and control groups each contained 10 animals. ESWT was applied 7 days before the surgical intervention, whereas the control group received no treatment. Follow-up evaluation was performed on postoperative day 5. The mean area of flap necrosis, expressed as a percentage of the total flap area, was calculated. A significant reduction of the average flap necrosis area was observed in the ESWT group (27.2% ± 9.6%) compared with the control group (46.1% ± 7.9% ($P < 0.05$).

In summary, this study indicates that preoperative ESWT may enhance skin flap survival in a rodent model.

Key Words: shock wave therapy, ischemic reperfusion injury, preconditioning, improving flap survival rate

(*Ann Plast Surg* 2009;63: 682–684)

Failure of composite flaps, due to ischemia injury, remains a serious clinical problem. During the last decade several techniques have been established to improve the survival of flaps by an increase of the resistance to further ischemia. All these techniques seem to have in common that they expose and precondition the tissue to a sublethal degree of environmental stress, which may be applied by a variety of physical and pharmacological stimuli.[1]

Recent studies reported an induction of angiogenesis together with release of angiogenic factors mediated through extracorporeal shock wave (ESW).[2–5] Animal studies in a rat model showed that ESW enhances the distal area of skin flaps, while ESW application was admitted immediately after the operation.[2,3,6] The present study was thus designed to examine whether ESW therapy also is effective in the preoperative treatment to ameliorate flap survival.

MATERIALS AND METHODS

Male adult Wistar rats with a weight between 200 and 300 g were used. All animals were maintained in accordance to the guidelines of the German Animal Welfare Act. The experimental protocol was approved by a review committee of the state of Baden-Wurttemberg, Germany. Seven days before the surgical intervention all animals were anesthetized with an intraperitoneal injection of ketamine hydrochloride (100 mg/kg; Ketanest 100 mg/mL; Fort Dodge Laboratories, Fort Dodge, Iowa) and xylazine (5 mg/kg; Rampun; Bayer Corp, Stilwell, Kansas) and randomly divided into 2 groups (ESW group and control group) of 10 animals each.

Epigastric Skin Flap Surgical Procedure

The operative procedure was identical for all groups. All operative procedures were performed under aseptic conditions. Animals were anesthetized with an intraperitoneal injection of ketamine hydrochloride (100 mg/kg; Ketanest 100 mg/mL; Fort Dodge Laboratories) and xylazine (5 mg/kg; Rampun; Bayer Corp). With the animals in a state of deep anesthesia, an extended epigastric adipocutaneous flap (6 × 10 cm) based on the left superficial epigastric vessels was raised. The right superficial epigastric vessels were ligated and the flap was sutured back to its native configuration and placed onto a silicon sheet to prevent neovascularization. To avoid autocannibalism, protective collars made of plastic film were applied to all the animals.[7]

ESW Group

Rats were placed in a supine position and an epigastric flap measuring 10 × 6 cm was outlined with a permanent marker on the abdominal skin. Ultrasound transmission gel was used as a contact medium between the ESW apparatus and skin. Shock wave was applied one-time in a dose of 500 impulses at 0.11 mJ/mm^2 and 8 Hz, using an electrohydraulic shock wave device with focusing applicator (dermaPACE, Sanuwave Inc., Marietta, GA) to the right upper corner of the flap. This area represents the random portion of the flap that predictably undergoes necrosis.[3,6,7]

The reason for the dosage and the timing that we applied ESW of 500 impulses at 0.11 mJ/mm^2 followed previous experiences.[2,3,8–11]

Control Group

In this group the flap was raised and sutured back without preoperative ESW treatment.

Evaluation

Follow-up evaluation was performed on postoperative day 5. Therefore all animals were killed and standardized digital pictures of the flap were taken and transferred to the computer (Fig. 1A, B). The mean area of flap necrosis, defined by surgical borders (expressed as a percentage of the total flap area) was calculated for each animal, using a self-programmed planimetry software. The results were expressed as percentage relative to surface area of the total flap.

All values were calculated as mean ± SD. Statistical analysis was performed with F and Student *t* test. A *P* value of less than 0.05 was considered statistically significant.

RESULTS

No animal was eliminated from the study because of infection, seroma, hematoma formation, or autocannibalization. There

Received September 11, 2008, and accepted for publication, after revision, January 4, 2009.

From the *Department of Plastic and Hand Surgery, Burn Center, BG Trauma Center, Ludwigshafen, Germany; †Department of Plastic and Hand Surgery, University of Heidelberg, Ludwigshafen, Germany; ‡Endocrine Laboratory, Laboratory Group, Heidelberg, Germany; and §Department of Plastic and Reconstructive Surgery, Leopold-Franzens University, Innsbruck, Austria.

Reprints: Holger Engel, MD, Department of Plastic and Hand Surgery, Burn Center, BG Trauma Center Ludwigshafen; Department of Plastic and Hand Surgery, The University of Heidelberg, Ludwig-Guttmann Str. 13, 67071 Ludwigshafen, Germany, E-mail: HolgerEngel@email.de.

ISSN: 0148-7043/09/6306-0682
DOI: 10.1097/SAP.0b013e31819ae048

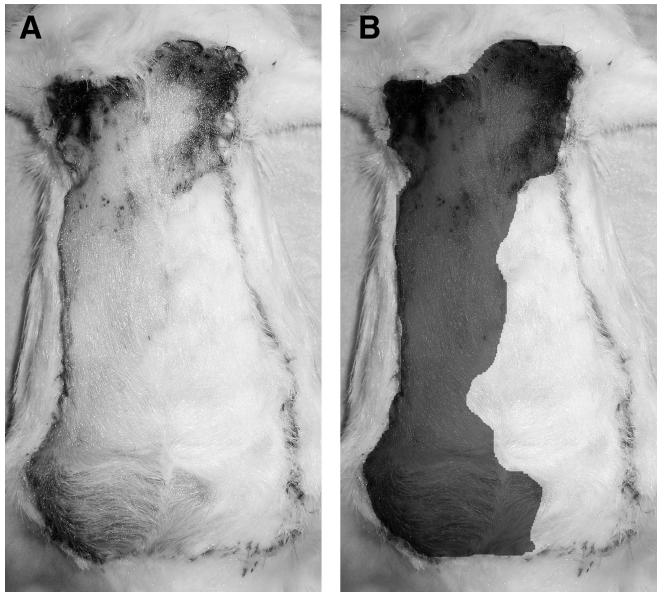

FIGURE 1. A, B, Characteristic sample of the control group at day 5 after surgery. The necrotic zone of the flap was measured by using a self programmed planimetry software.

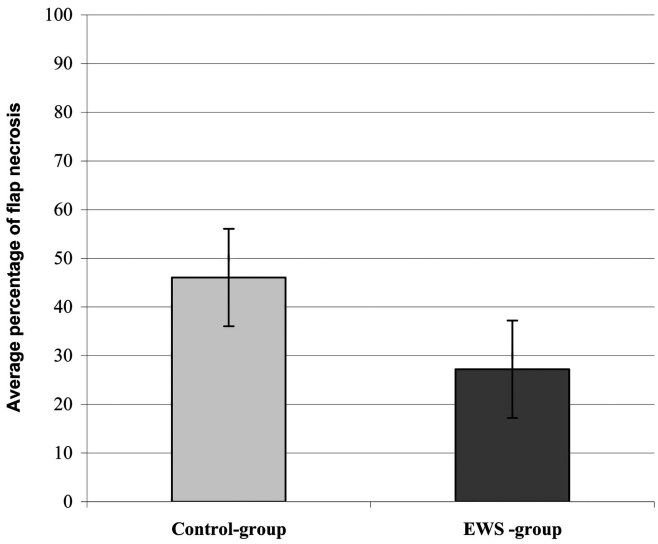

FIGURE 2. Diagram showing the percentage of flap necrosis in the EWS group compared with the control group.

was a significant increase of the average surviving area of the ESW-group compared with the control group ($P < 0.05$). The ESW group showed an average flap necrosis of 27.2% ± 9.6%, whereas the control group had an average area of flap necrosis of 46.1% ± 7.9% (Fig. 2).

DISCUSSION

Skin flap necrosis in the distal flap areas is still a major challenge in reconstructive surgery and several techniques have been described to improve blood supply and tissue perfusion in compromised tissues.

Previous animal studies suggest that ESW treatment has a positive effect in rescuing ischemic zone of flap by an increase of tissue perfusion. ESW treatment was first introduced into medicine for the treatment of urolithiasis, but has been widely adopted for a number of musculoskeletal disorders including nonunion of long bone fractures, calcifying tendonitis, or plantar fasciitis.[12–15] Low energy shock ESW therapy effectively induced angiogenesis and improved chronic ischemia in animals and humans.[16–18] Further studies showed a significant rise of growth factors such as VEGF as well as endothelial nitric oxide synthase and proliferating cell nuclear antigen after ESW treatment.[2] With regard to plastic surgery perspectives, ESW therapy has recently been demonstrated to improve skin flap survival.[2,3,6] In all these studies ESW was applied immediately after the surgical intervention. Thus, the purpose of this study was to determine the preoperative effect of ESW as a noninvasive technique to precondition flap tissue. According to the findings from earlier reports, our current study confirms an enhanced flap survival in the animal model. Although the exact mechanism of ESW therapy remains unknown, we hypothesize that mechanical forces of the ESWT stimulate cell proliferation and vascular remodeling in living skin. As cell growth and vascular supply are critical to wound healing and tissue expansion, devices applying controlled mechanical loads to tissues may be a powerful therapy to increase growth factors induced in-growth of neovascular formation. This is an early study in the preoperative treatment with ESW for flap tissue. Because of limitation of our experimental design further studies are planned to determine the mechanisms which are involved in the effectiveness of ESWT. Although several approaches have been developed to reduce ischemic skin flap necrosis, the potential of ESW treatment looks very promising avoiding complications or adverse effects.[4,16,17,19]

As a result, the study indicates that preoperative ESW treatment may enhance skin flap survival in a rodent model, proving its potential to become a viable, noninvasive, and cost-effective method to improve the blood supply in ischemic tissue.

REFERENCES

1. Harder Y, Amon M, Laschke MW, et al. An old dream revitalised: preconditioning strategies to protect surgical flaps from critical ischaemia and ischaemia-reperfusion injury. *J Plast Reconstr Aesthet Surg*. 2008; 61:503–511.
2. Kuo YR, Wu WS, Hsieh YL, et al. Extracorporeal shock wave enhanced extended skin flap tissue survival via increase of topical blood perfusion and associated with suppression of tissue proinflammation. *J Surg Res*. 2007;143: 385–392.
3. Meirer R, Brunner A, Deibl M, et al. Shock wave therapy reduces necrotic flap zones and induces VEGF expression in animal epigastric skin flap model. *J Reconstr Microsurg*. 2007;23:231–236.
4. Oi K, Fukumoto Y, Ito K, et al. Extracorporeal shock wave therapy ameliorates hind limb ischemia in rabbits. *Tohoku J Exp Med*. 2008;214:151–158.
5. Wang CJ, Wang FS, Yang KD, et al. Shock wave therapy induces neovascularization at the tendon-bone junction. A study in rabbits. *J Orthop Res*. 2003;21:984–989.
6. Meirer R, Kamelger FS, Huemer GM, et al. Extracorporal shock wave may enhance skin flap survival in an animal model. *Br J Plast Surg*. 2005;58:53–57.
7. Engel H, Sauerbier M, Germann G, et al. Dose-dependent effects of a nitric oxide donor in a rat flap model. *Ann Plast Surg*. 2007;58:456–460.
8. Adanali G, Seyhan T, Turegun M, et al. Effects of different vascular patterns and the delay phenomenon on rat ventral island flap viability. *Ann Plast Surg*. 2002;48:660–664.
9. Holzbach T, Neshkova I, Vlaskou D, et al. Searching for the right timing of surgical delay: angiogenesis, vascular endothelial growth factor and perfusion changes in a skin-flap model. *J Plast Reconstr Aesthet Surg*. 2008 Sep 22. [Epub ahead of print].
10. Huemer GM, Froschauer SM, Pachinger T, et al. A comparison of pretreatment with a topical combination of nonivamide and nicoboxil and surgical delay in a random pattern skin flap model. *J Plast Reconstr Aesthet Surg*. 2009;62:914–919.

11. Lineaweaver WC, Lei MP, Mustain W, et al. Vascular endothelium growth factor, surgical delay, and skin flap survival. *Ann Surg*. 2004;239:866–873; discussion 873–865.
12. Chaussy C, Schuller J, Schmiedt E, et al. Extracorporeal shock-wave lithotripsy (ESWL) for treatment of urolithiasis. *Urology*. 1984;23:59–66.
13. Eisenberger F, Chaussy C. Contact-free renal stone fragmentation with shock waves. *Urol Res*. 1978;6:111.
14. Wang CJ. An overview of shock wave therapy in musculoskeletal disorders. *Chang Gung Med J*. 2003;26:220–232.
15. Wang CJ, Huang HY, Chen HH, et al. Effect of shock wave therapy on acute fractures of the tibia: a study in a dog model. *Clin Orthop Relat Res*. 2001:112–118.
16. Fukumoto Y, Ito A, Uwatoku T, et al. Extracorporeal cardiac shock wave therapy ameliorates myocardial ischemia in patients with severe coronary artery disease. *Coron Artery Dis*. 2006;17:63–70.
17. Nishida T, Shimokawa H, Oi K, et al. Extracorporeal cardiac shock wave therapy markedly ameliorates ischemia-induced myocardial dysfunction in pigs in vivo. *Circulation*. 2004;110:3055–3061.
18. Aicher A, Heeschen C, Sasaki K, et al. Low-energy shock wave for enhancing recruitment of endothelial progenitor cells: a new modality to increase efficacy of cell therapy in chronic hind limb ischemia. *Circulation*. 2006;114: 2823–2830.
19. Uwatoku T, Ito K, Abe K, et al. Extracorporeal cardiac shock wave therapy improves left ventricular remodeling after acute myocardial infarction in pigs. *Coron Artery Dis*. 2007;18:397–404.

